

Mayerly Nava, Freddy Romero, Yasmir Quiroz, Gustavo Parra, Lizette Bonet and Bernardo Rodríguez-Iturbe

Am J Physiol Renal Physiol 279:910-918, 2000.

You might find this additional information useful...

This article cites 55 articles, 7 of which you can access free at:

<http://ajprenal.physiology.org/cgi/content/full/279/5/F910#BIBL>

This article has been cited by 12 other HighWire hosted articles, the first 5 are:

IL-6/IL-6R Axis Plays a Critical Role in Acute Kidney Injury

Y. Nechemia-Arbely, D. Barkan, G. Pizov, A. Shriki, S. Rose-John, E. Galun and J. H. Axelrod
J. Am. Soc. Nephrol., June 1, 2008; 19 (6): 1106-1115.

[Full Text] [PDF]

Melatonin ameliorates oxidative stress, inflammation, proteinuria, and progression of renal damage in rats with renal mass reduction

Y. Quiroz, A. Ferrebuz, F. Romero, N. D. Vaziri and B. Rodríguez-Iturbe
Am J Physiol Renal Physiol, February 1, 2008; 294 (2): F336-F344.

[Abstract] [Full Text] [PDF]

Aging impairs neurogenic contraction in guinea pig urinary bladder: role of oxidative stress and melatonin

P. J. Gomez-Pinilla, M. J. Pozo and P. J. Camello

Am J Physiol Regulatory Integrative Comp Physiol, August 1, 2007; 293 (2): R793-R803.

[Abstract] [Full Text] [PDF]

Mycophenolate mofetil administration reduces renal inflammation, oxidative stress, and arterial pressure in rats with lead-induced hypertension

Y. Bravo, Y. Quiroz, A. Ferrebuz, N. D. Vaziri and B. Rodríguez-Iturbe
Am J Physiol Renal Physiol, August 1, 2007; 293 (2): F616-F623.

[Abstract] [Full Text] [PDF]

Mycophenolate Mofetil Treatment Improves Hypertension in Patients with Psoriasis and Rheumatoid Arthritis

J. Herrera, A. Ferrebuz, E. G. MacGregor and B. Rodríguez-Iturbe

J. Am. Soc. Nephrol., December 1, 2006; 17 (12_suppl_3): S218-S225.

[Abstract] [Full Text] [PDF]

Medline items on this article's topics can be found at <http://highwire.stanford.edu/lists/artbytopic.dtl> on the following topics:

Biochemistry .. Catalases
Biochemistry .. Glutathione Peroxidase
Biochemistry .. Oxidative Stress
Oncology .. Melatonin
Oncology .. Oxidative Damage
Medicine .. Acute Kidney Failure

Updated information and services including high-resolution figures, can be found at:

<http://ajprenal.physiology.org/cgi/content/full/279/5/F910>

Additional material and information about *AJP - Renal Physiology* can be found at:

<http://www.the-aps.org/publications/ajprenal>

This information is current as of November 23, 2009 .

Melatonin attenuates acute renal failure and oxidative stress induced by mercuric chloride in rats

MAYERLY NAVA,¹ FREDDY ROMERO,² YASMIR QUIROZ,² GUSTAVO PARRA,^{1,3}
LIZETTE BONET,¹ AND BERNARDO RODRÍGUEZ-ITURBE^{1,2}

¹Renal Service and Laboratory, Hospital Universitario, ²Instituto de Investigaciones Biomédicas, Fundacite-Zulia, and ³Center of Experimental Surgery, Universidad del Zulia, Maracaibo 4001-a, Venezuela

Received 11 February 2000; accepted in final form 31 July 2000

Nava, Mayerly, Freddy Romero, Yasmir Quiroz, Gustavo Parra, Lizette Bonet, and Bernardo Rodríguez-Iturbe. Melatonin attenuates acute renal failure and oxidative stress induced by mercuric chloride in rats. *Am J Physiol Renal Physiol* 279: F910–F918, 2000.—We evaluated the effect of melatonin (Mel), a potent scavenger of reactive oxygen species, in the course of HgCl₂-induced acute renal failure. Rats received by gastric gavage 1 mg/kg of Mel (*n* = 21) or vehicle (*n* = 21), 30 min before the subcutaneous injection of HgCl₂ (2.5 mg/kg). Rats were killed at 24, 48, and 72 h, and plasma creatinine (S_{cr}), renal histology, proliferative activity, apoptosis, and superoxide-producing cells were studied. We also determined the renal content of malondialdehyde (MDA) and glutathione (GSH) and the activities of glutathione peroxidase and catalase. Mel pretreatment (Mel plasma levels of 3.40 ± 3.15 μg/ml at the time of HgCl₂ injection) prevented the increment in S_{cr} and reduced tubular necrosis from 41.0 ± 10.5 to 4.2 ± 5.1% of proximal tubules (*P* < 0.01). Apoptosis and postnecrotic proliferative activity were twice more intense in the group untreated with Mel. Increment in renal content of MDA and decrease in GSH resulting from HgCl₂ toxicity were prevented by Mel. Mel also induced an important reduction in superoxide-positive cells. In contrast to the beneficial effects of pretreatment with Mel, the administration of Mel in conjunction with HgCl₂ had no effect on the oxidative damage and did not prevent nephrotoxicity. We conclude that the beneficial effects of pharmacological doses of Mel are due to its antioxidant properties.

nephrotoxic acute renal failure

MERCURIC CHLORIDE (HgCl₂) has been widely used to study the pathophysiology of nephrotoxic acute renal failure. Hemodynamic changes, functional alterations, and histological damage in this experimental model are well characterized (16, 50, 55) and include activation of the renin-angiotensin system, profound renal vasoconstriction, reduction in glomerular filtration rate, and progressive azotemia. The renal damage is particularly severe in the proximal tubule. Treatment strategies have been mostly directed to correct the hemodynamic disturbances or the toxic effects of the metal (14, 17, 39, 52, 54).

Reactive oxygen species (ROS) have been increasingly implicated as mediators of damage in ischemic, toxic, and immune-mediated tissue injuries (23, 26, 57). In HgCl₂-induced nephrotoxicity, the reduction in renal content of antioxidants such as glutathione (GSH), as well as the decrease of thiol groups, has been advanced as evidence of the role of ROS in this pathology (21, 22). Furthermore, morphological and biochemical studies have shown that HgCl₂ toxicity is associated with a substantial loss of ATP-generating mitochondrial inner membrane surfaces and important loss of activity of the free radical scavenger systems, such as superoxide dismutase and glutathione peroxidase (GSH-Px) (58). However, the evidence for the pathogenic role of oxidant stress in this condition is conflicting. Some (4, 24, 33, 60), but not all (2, 38), studies have demonstrated increased peroxide formation in the kidney and, in addition, the administration of several antioxidants has failed to provide a consistent beneficial effect in this condition (18, 36).

Melatonin (Mel) is the chief secretory product of the pineal gland and has a very potent antioxidant activity, depending mainly on its capacity to act as electron donor (51, 41). In vivo and in vitro, Mel has been found to protect tissues against oxidative damage generated by a variety of toxic agents (reviewed in 7) and metabolic processes, including chemotherapy-induced toxicity (32) and ischemia-reperfusion injury in stomach, liver, and brain (13, 19, 29, 48). More pertinently, Mel has recently been found to protect against adriamycin-induced nephrotoxicity (35). Mel is widely available, relatively free of side effects, rapidly active after oral administration, and commonly used in humans in the treatment of insomnia (8). Therefore, we decided to investigate the effect of Mel in the course of nephrotoxic acute renal failure induced by HgCl₂. Our results indicate that pretreatment with Mel improves dramatically the histological and functional damage and the lipid peroxidation in this experimental model.

Address for reprint requests and other correspondence: B. Rodríguez-Iturbe, Apartado Postal 1430, Maracaibo 4001-a, Venezuela (E-mail: bri@iamnet.com).

The costs of publication of this article were defrayed in part by the payment of page charges. The article must therefore be hereby marked "advertisement" in accordance with 18 U.S.C. Section 1734 solely to indicate this fact.

MATERIAL AND METHODS

Experimental Design

Studies were done in male Sprague-Dawley rats, weighing 200–250 g and fed on a standard rat chow and ad libitum water ingestion. HgCl₂ (2.5 mg/kg body wt in 0.5 ml 0.9% saline solution) was administered subcutaneously to each one of two groups of rats: 1) HgCl₂-Mel group, consisting of 21 rats that received Mel (1 mg/kg) by gastric gavage, 30 min before injection and 2) HgCl₂ group, consisting of 21 rats that received vehicle (saline solution) instead of Mel by gastric gavage. An additional group of 15 rats received 0.5 ml of 0.9% saline subcutaneously (instead of HgCl₂) and served as a control group. Five to seven rats from each group were killed 24, 48, and 72 h after HgCl₂ by aortic desanguination under ether anesthesia. The kidneys were perfused with iced 0.9% saline solution, removed, and used for histological and biochemical studies.

Plasma levels of Mel were determined in five rats at 30 min (corresponding to the time of HgCl₂ injection), 2 h, and 5 h after administration. Plasma creatinine (S_{cr}) was determined daily by autoanalyzer methodology. In a separate set of studies, designed to evaluate the effects of Mel administered after HgCl₂, rats were given the same dose of Mel at the same time as the injection of the nephrotoxic agent (*n* = 5).

Histological Studies

Coronal sections of one kidney were snap-frozen in dry ice and acetone as well as fixed in 15% Formalin and embedded in Paraplast Plus (Monoject, Sherwood Medical Scientific Division, St. Louis MO). Sections (3 μm) were stained with hematoxylin and eosin, Masson's trichrome stain, and periodic acid/Schiff reagent.

Identification of proliferating cells. As described previously (49), 4-μm frozen sections fixed in 4% paraformaldehyde were used in the study of proliferating cell nuclear antigen (PCNA) by the avidin-biotin-peroxidase technique. Briefly, sections were postfixed in 100 and 95% ethanol, incubated for 10 min in 3% H₂O₂, washed with PBS, and incubated with avidin (2 μg/ml, Sigma, St. Louis MO) for 20 min, and after being washed with PBS, incubated with 0.001% biotin solution (Sigma) for 20 min. Afterward, sections were incubated for 90 min with monoclonal anti-PCNA antibody (Zymed Laboratories, San Francisco, CA) diluted 1:20 in Tris-buffered saline (TBS), pH 7.8. Subsequently, the sections were incubated with 2.5% low-fat milk solution in TBS for 15 min and then treated with biotinylated F(ab')₂ rat anti-mouse IgG antibody (Organon Teknica, Cappel, Durham, NC) at a dilution of 1:20 in TBS for 1 h. Finally, sections were washed in TBS and incubated with peroxidase-conjugated extravidin (Sigma) for 35 min. The reaction product was exposed by using 0.005% H₂O₂ containing 0.02% 3,3'-diaminobenzidine (DAB) in 50 mmol/l Tris (pH 7.6).

Identification of apoptosis. As described previously (49), frozen sections (4 μm) were fixed in 10% neutral-buffered Formalin and postfixed in ethanol:acetic acid for 5 min at -20°C. Fragmented DNA was terminal deoxynucleotidyl transferase (TdT)-mediated UTP-biotin nick-end labeled (TUNEL) by using an Apoptag in situ apoptosis detection kit (Oncor, Gaithersburg, MD). Embryonic rat forelimb bud tissue was used as a positive control. Negative controls were renal and forelimb bud tissues incubated with distilled water instead of the TdT enzyme in the reaction buffer. Slides were mounted with SlowFade (Molecular Probes) to delay fluorescence quenching.

Evaluation of histological findings. At least five sections of each biopsy were used for evaluation of PCNA-positive cells, TUNEL-positive cells, and severity of toxic damage by using a microscope (Axioscope, Zeiss; with epifluorescence device) with an ocular piece fitted with a grid. The number of PCNA- and TUNEL-positive cells per cubic millimeter in tubulointerstitial areas was counted as described previously (49). The extension of tubular injury was evaluated in terms of the percent area of the sections showing a given level of histological damage. The severity of the tubular lesions was classified according to the following criteria: no injury = intact tubules with normal tubular cells and preserved brush border; tubular cell damage = loss of the brush border, cytoplasmic extrusion into the lumen, and intraluminal cellular debris; focal tubular necrosis = patchy necrosis of tubular epithelial cells with intraluminal debris and preservation of the tubular basement membrane; and complete tubular necrosis = disruption of the tubular basement membrane and necrosis of the tubule.

Superoxide staining. Superoxide production in renal cells was studied in cryostat sections by the cytochemical method of Briggs et al. (7). Slides were incubated for 60 min at 37°C in the following staining solution: 50 ml 0.05 M Tris·HCl buffer, 1 ml DAB stock solution (5g DAB/132 ml Tris buffer, 0.05 M, pH 7.6), 250 μl 8% NiCl, 32.5 μl 10% NaN₃, and 50 μl 0.5 M MnCl₂. Sections were fixed with 10% Formalin for 10 min and counterstained with 1% methyl green.

Determination of Lipid Peroxidation

Malondialdehyde (MDA) in renal tissue was analyzed by the method of Ohkawa et al. (37). Sections of kidney obtained after cold perfusion as outlined earlier were placed in a total volume of cold 3 ml 100 mM KCl plus 0.003 M EDTA and homogenized. Homogenates were centrifuged at 600 *g* for 15 min. Four hundred microliters of supernatant were added to 0.2 ml 8.1% SDS, 1.5 ml 20% acetic acid (pH 3.5), 1.5 ml 0.8% thiobarbituric acid, and 0.6 ml water. This solution was heated to 95°C for 60 min. After addition of 1.0 ml water and 5.0 ml of *n*-butanol-pyridine mixture (15:1, vol/vol), the mixture was vigorously shaken and centrifuged at 2,000 *g* for 15 min. The absorbance of the upper layer was read at 532 nm (Shimadzu model UV21100S spectrophotometer, Kyoto, Japan). MDA bis-dimethyl acetal (Sigma) was used as the external standard. Results are expressed as nanomoles MDA per milligram protein. The intra-assay variability was deter-

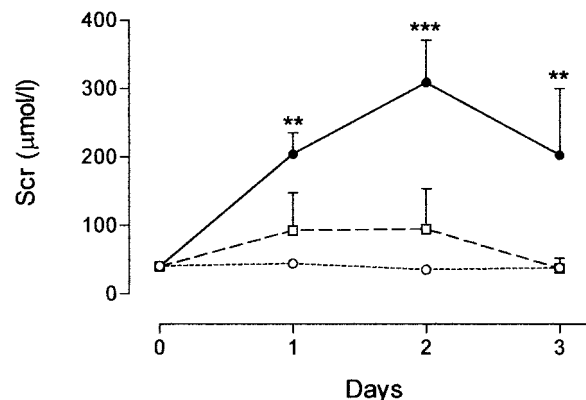


Fig. 1. Serum creatinine (S_{cr}) in rats receiving 2.5 mg of HgCl₂ by subcutaneous injection, 30 min after 1 mg/kg of melatonin (□) or vehicle (●). Control rats (○) received saline instead of HgCl₂. Error bars represent SD. ***P* < 0.01, ****P* < 0.001 vs. the group treated with melatonin.

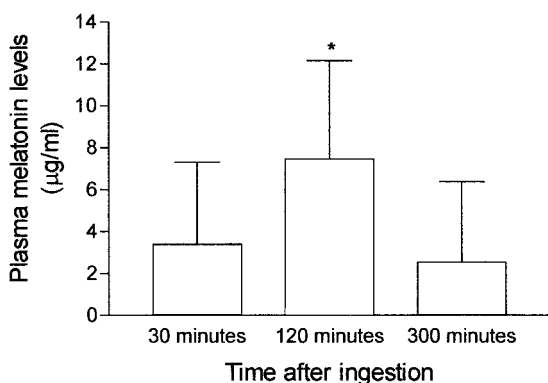


Fig. 2. Plasma melatonin levels 30, 120, and 300 min after oral administration of 1 mg/kg body wt. The injection of HgCl₂ in the studies was done 30 min after ingestion of melatonin. The physiological level at the time of the studies is 79.4 ± 30.4 µg/ml. Error bars represent SD. **P* < 0.05.

mined in five sets of triplicate samples, and the coefficient of variation was 8.9 ± 2.40%.

Determination of Kidney GSH

Renal GSH content was measured by a modification of the method of Beutler et al. (6). Renal tissue slices obtained after cold perfusion were suspended in 100 mM KCl plus 0.003 M EDTA and homogenized as described for the determination of MDA above. The homogenates were centrifuged at 600 *g* for 10 min, 1,000 µl of supernatant were added to 1.5 ml methaphosphoric acid, and particulate debris was removed by centrifugation at 3,000 *g* for 10 min. Reduced GSH was measured by adding 500 µl of supernatant to 2.0 ml of 0.2 M phosphate buffer and 0.25 ml 0.04% 5,5'-dithio-bis 2-nitrobenzoic acid. Absorbance was read at 410 nm. GSH (Sigma) was used as the external standard. GSH content was expressed as nanomoles of GSH per milligram homogenate protein. The intra-assay variability was determined in five sets of triplicate samples (0.82 ± 0.38%).

Determination of Kidney GSH-Px

Renal GSH-Px activity was measured by the method of Lawrence and Burk (30). The reaction mixture consisted of 50 mM potassium phosphate buffer: (in mM) 1 EDTA, 1 NaN₃, 0.2 NADPH, 1 GSH, and 0.25 H₂O₂, as well as 1 U/ml GSSG reductase, pH 7, in a total volume of 1 ml. Enzyme source (0.1 ml) was added to 0.8 ml of the above mixture and allowed to incubate for 5 min at room temperature, before initiation of the reaction by the addition of 0.1 ml peroxide solution. Absorbance at 340 nm was recorded for 2 min, and the activity was calculated by using the extinction coefficient of NADPH at 340 nm, 6.22 mM/cm. The result was expressed

as nmoles NADPH oxidized per minute per mg of protein. Intra-assay variability was 4.32 ± 2.0%.

Determination of Kidney Catalase Activity

Catalase activity was determined following the method of Aebi (3). Slices of renal tissue obtained as before were transferred to tubes containing 50 mM potassium phosphate, pH 7.0, and homogenized. The homogenates were centrifuged at 600 *g* for 10 min. Twenty-five microliters of the supernatant were added to 725 µl of a mixture containing 7.7 mM H₂O₂ in 10 mM phosphate buffer, pH 7.0. The change in absorbance was read at 240 nm. The rate constant of a first-order reaction (*k*) was used: $k = (1/\Delta t) \times \ln (A1/A2)$, where Δt is a measured interval (30 s) and A1 and A2 are the absorbances at initial and final measurement times, respectively. Catalase activity was expressed as *k* per milligram homogenate protein. Intra-assay variability was 4.89 ± 2.63%.

Determination of Mel Levels

Mel levels in plasma were determined by RIA with commercially available kits (Alpco Melatonin RIA, RK-Mel). The Mel extraction from samples was made with reverse-phase extraction columns provided in the kit. The sample application volume was reduced (0.125–0.750 ml instead of 1 ml). The extracts were reconstituted with RIA buffer. Because the plasma Mel levels after oral ingestion of Mel fell in the micrograms per milliliter range, the samples were diluted 162.408 or 1.786.488 times. Sensitivity of the method is 0.3 pg/ml. The intra-assay variability of the column extraction and RIA combined was 7.8 ± 1.4%.

Statistical Analysis

Statistical analysis was done with the help of a commercial statistical package (Instat GraphPad) using nonparametric methods (Kruskall-Wallis or Mann-Whitney tests for differences between groups and Friedman tests for serial changes), followed by Dunn's posttests when *P* < 0.05. Results are expressed as means ± SD.

RESULTS

Figure 1 shows the serial changes in S_{cr} concentration in the experimental and control groups. Rats in the HgCl₂ group had an increase in S_{cr} that reached a peak 48 h after the administration of the toxic agent (309.4 ± 56.5 µmol/l). In contrast, the rats given Mel (HgCl₂-Mel group) had significantly lower levels (100.1 ± 20.3 µmol/l, *P* < 0.001). Plasma Mel levels are shown in Fig. 2. The baseline Mel levels before the studies are 79.4 ± 30.45 µg/ml. After ingestion of 1 mg/kg of Mel, pharmacological levels in the microgram range are obtained rapidly, peak at ~2 h, and remain

Table 1. *Histological findings in proximal tubular cells*

	24 h		48 h		72 h	
	HgCl ₂	HgCl ₂ + Mel	HgCl ₂	HgCl ₂ + Mel	HgCl ₂	HgCl ₂ + Mel
No injury, %	10.1 ± 8.5	28.6 ± 19.4	2.1 ± 4.3	26.6 ± 9.4†	15.5 ± 18.2	54.2 ± 14.0*
Cellular damage, %	29.4 ± 8.3	38.4 ± 14.2	21.4 ± 7.9	39.5 ± 9.9†	26.2 ± 18.3	27.7 ± 12.5
Focal necrosis, %	30.5 ± 4.9	27.8 ± 11.1	46.6 ± 7.4	24.9 ± 11.6†	45.6 ± 11.4	11.3 ± 10.7*
Complete tubular necrosis, %	25.6 ± 17.2	0 ± 0	41.0 ± 10.5	4.2 ± 5.1†	36.2 ± 4.3	6.9 ± 6.89†

Values are means ± SD; *n* = 5–7 biopsies/group at each time point. Renal histology of tubular injury is expressed as the %area examined presenting the corresponding finding. Statistical significance vs. HgCl₂ group: **P* < 0.05, †*P* < 0.01.

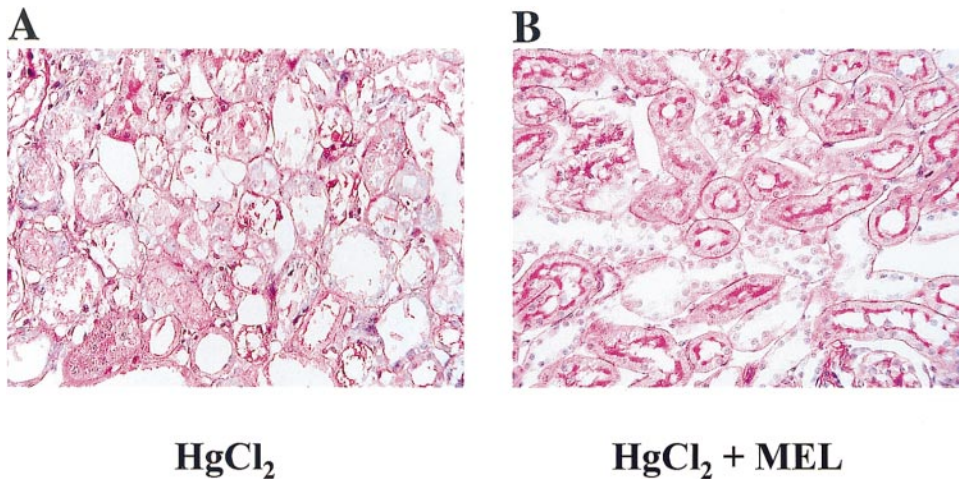


Fig. 3. Histology in renal biopsies obtained 48 h after HgCl₂ injection. A: severe damage characterized by areas of complete proximal tubular necrosis with disruption of the tubular basement membrane in a rat not treated with melatonin. B: a milder lesion observed in a rat pretreated with melatonin (areas of focal tubular necrosis and tubular cell damage are present). Periodic acid/Schiff staining. Magnification: $\times 400$.

in that range for at least 5 h. As shown in Fig. 2, at the time when HgCl₂ is injected (30 min after oral administration of Mel) the Mel levels are already 3.40 ± 3.15 $\mu\text{g/ml}$.

The histological observations are shown in Table 1. Toxic damage in the untreated rats was more intense on *day 2*, when $41 \pm 10.5\%$ of the tubules were completely necrotic (Fig. 3A). Diffuse tubular necrosis was still present in more than one-third of the tubules on *day 3*. In contrast, the extension of completely necrotic tubules was reduced nine times in the rats treated with Mel at the same time intervals (Table 1 and Fig. 3B).

Proliferating cells in the tubulointerstitial areas were observed from the first day in both experimental groups and increased importantly 48 and 72 h after the nephrotoxic insult. In the HgCl₂ group, the number of PCNA-positive cells increased 20 times during this period, a proliferative reaction twice more intense than in the HgCl₂-Mel group ($P < 0.01$, Fig. 4). The concomitant apoptosis is shown in Fig. 5, demonstrating that TUNEL-positive cells were present since the first day and increased to a maximal value on *day 3*. Apoptosis

was also significantly higher in the untreated group than in the Mel on *days 1, 2, and 3* after HgCl₂ administration (Fig. 5). Figure 6 shows the histological findings of proliferating (A and B) and apoptotic cells (C and D).

In control (vehicle-treated) rats, superoxide-producing cells were very rare (0.43 ± 0.01 superoxide-positive cells/100 tubulointerstitial cells). In the HgCl₂ group, the first day after mercury administration there were 10.3 ± 3.2 superoxide-positive cells/100 tubulointerstitial cells, and increased numbers remained 48 and 72 h later. Mel treatment reduced the number of superoxide-positive cells to control levels (Fig. 7). Representative microphotographs are shown in Fig. 8, A and B.

Figure 9 shows the renal content of MDA. In the HgCl₂ group, MDA doubled on *day 1* after HgCl₂ injection (0.47 ± 0.05 nmol/mg protein, $P < 0.01$). Rats treated with Mel had lower MDA content ($P < 0.05$ vs. the HgCl₂ group). As shown in Fig. 10, GSH content of the kidney in the HgCl₂ group decreased the first day and returned to control levels at *day 3*. The fall in GSH

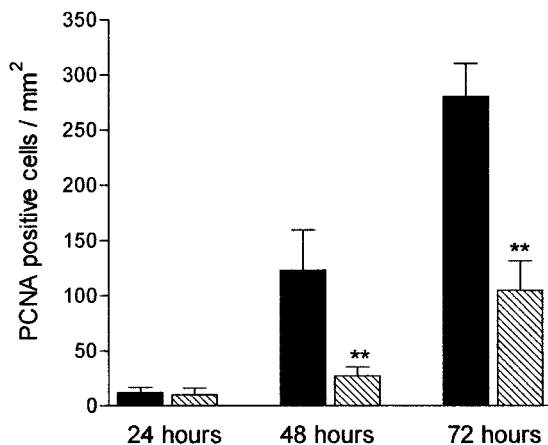


Fig. 4. Proliferating cells [proliferating cell nuclear antigen (PCNA)-positive cells/ mm^2] in acute renal failure induced by subcutaneous injection of 2.5 mg of HgCl₂ in rats that received 30 min before melatonin (hatched bars) or vehicle (filled bars). Error signs are SD. $**P < 0.01$ vs. the corresponding paired bar.

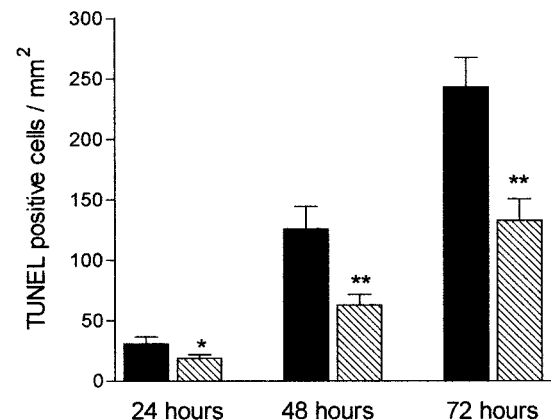
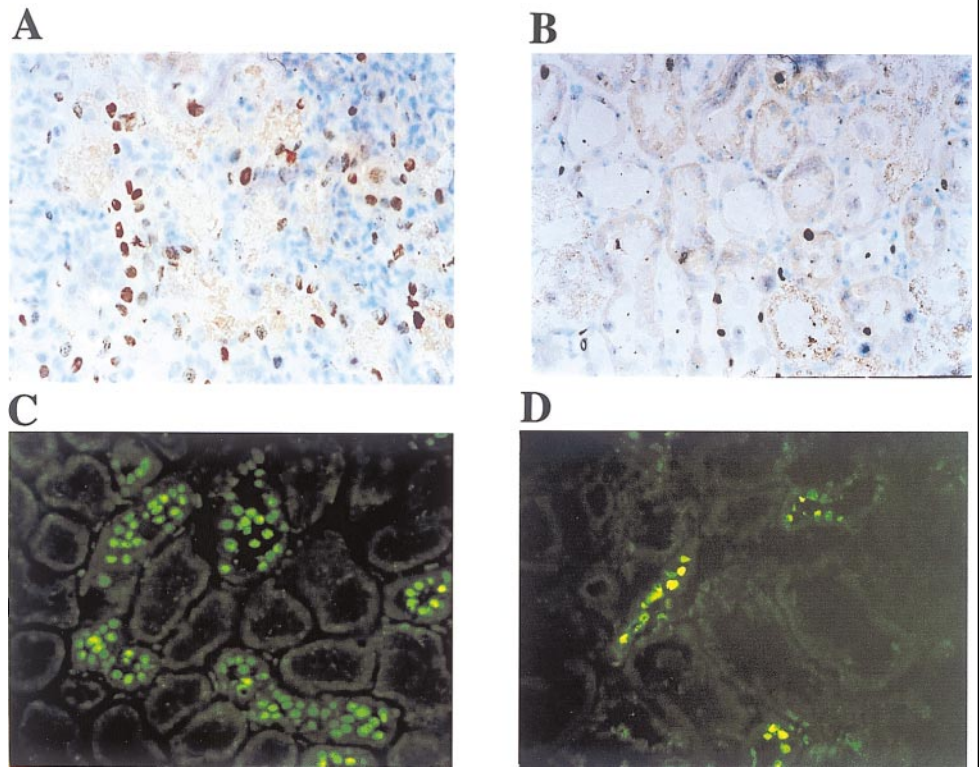


Fig. 5. Apoptosis detected by the terminal deoxynucleotidyl transferase (TdT)-mediated UTP-biotin nick-end labeling (TUNEL) technique (TUNEL-positive cells/ mm^2 in tubulointerstitial areas) in rats receiving HgCl₂ and melatonin (hatched bars) or vehicle (filled bars). Error signs are SD. $*P < 0.05$, $**P < 0.01$ vs. the corresponding paired bar.

Fig. 6. Proliferating cells (PCNA-positive cells, immunoperoxidase staining) and apoptotic cells (TUNEL fluorescein-positive cells) in renal biopsies obtained 48 h after the injection of HgCl₂. Proliferating cells and apoptotic cells are more numerous in the rat untreated with melatonin (A and C) than in the rat pre-treated with melatonin (B and D). Areas of the biopsies selected for the figure exclude areas presenting focal or complete tubular necrosis.



content was less marked (3.25 ± 0.2 nmol/mg protein) and less prolonged (normal values of 7.46 ± 2.77 2 nmol/mg protein at *day 2*) in the group that received Mel (Fig. 10). GSH-Px activity was reduced significantly ($P < 0.01$) the first day after HgCl₂ in the HgCl₂ group (65.3 ± 8.4) and in the HgCl₂-Mel group (74.8 ± 14.2) in relation to control (100.5 ± 16.6 nmol NADPH oxidized·min⁻¹·mg protein⁻¹). The difference between the experimental groups was not significantly different. *Day 3* studies showed that GSH-Px activity had partially recovered in both experimental groups (HgCl₂-Mel = 82.7 ± 12 , $P > 0.05$ vs. control; HgCl₂ group = 72.5 ± 16.7 nmol NADPH oxidized·min⁻¹·mg protein⁻¹, $P < 0.01$ vs. control).

Figure 11 shows the renal catalase activity: Mel treatment induced an increment in catalase activity

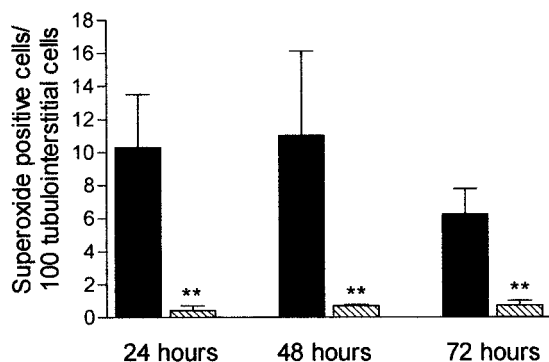


Fig. 7. Number of superoxide-producing cells in renal biopsies of rats obtained 24, 48, and 72 h after receiving HgCl₂ and vehicle (filled bars) or HgCl₂ and melatonin (hatched bars). Error bars are SD. ** $P < 0.01$ vs. corresponding paired column.

that was more pronounced at *day 1* (0.64 ± 0.04 k/mg protein, $P < 0.01$ vs. HgCl₂ and control groups). After the second day, catalase activity was comparable in the experimental groups.

Administration of Mel at the Same Time of HgCl₂

The administration of 1 mg/kg body weight of melatonin at the same time of HgCl₂ failed to protect against the toxic effects of the metal. Studies done in five rats showed that S_{cr} levels at 24 h were 238.7 ± 79.7 μmol/l, similar to the levels found when HgCl₂ was administered alone (see Fig. 1).

Histological findings were as follows. 1) At 24 h, no injury = $8.5 \pm 4.08\%$, cellular damage = $20.0 \pm 7.4\%$, focal necrosis = $46.3 \pm 14.4\%$, and complete necrosis = $27.3 \pm 11.5\%$. 2) At 48 h, no injury = 0% , cellular damage = $7.0 \pm 6.1\%$, focal necrosis = $53.0 \pm 7.9\%$, and complete necrosis = $39.9 \pm 10.1\%$. 3) At 72 h, no injury = $1.1 \pm 1.6\%$, cellular damage = $19.2 \pm 8.3\%$, focal necrosis = $59.2 \pm 1.2\%$, and complete necrosis = $20.6 \pm 5.5\%$. There are no significant differences between these histological findings and the findings present in the group that received only HgCl₂ (shown in Table 1).

Twenty-four hours after the administration of the toxic agent in conjunction with Mel, the renal content of MDA (0.42 ± 0.09 nmol/mg protein), GSH (2.08 ± 0.91 nmol/mg protein), and activities of GSH-Px (62.2 ± 5.0 nmol·min⁻¹·mg of protein⁻¹) and catalase (0.33 ± 0.05 k/mg protein) were not different from the values obtained when HgCl₂ was administered alone.

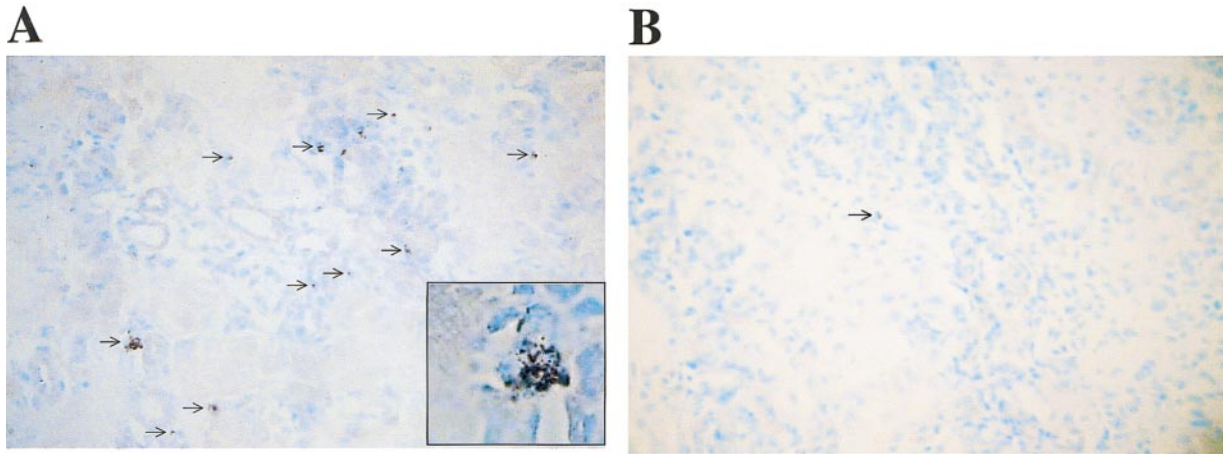


Fig. 8. Superoxide-positive cells (arrows) in low-magnification microphotographs in biopsies taken 24 h after the administration of HgCl₂+vehicle (A) or HgCl₂+Mel (B). *Inset*: higher magnification of superoxide-producing cells in the proximal tubule.

DISCUSSION

The experimental model of acute renal failure induced by HgCl₂ is characterized by intense vasoconstriction, decrease in glomerular filtration rate, tubular collapse, and marked structural and functional tubular abnormalities. Treatment strategies directed to prevent or improve the renal hemodynamic conditions in this experimental model have met with variable degrees of success: among them are suppression of the renin-angiotensin system (14, 16), increase in the urine flow (52), administration of vasodilating prostaglandins (39), inhibition of thromboxane synthesis (54), and administration of a nonspecific hemorrhheologic agent, pentoxifylline (53). Other investigations have focused on the use of sulfhydryl-reducing agents and found that treatment of dithiothreitol improved the course of mercury-induced acute renal failure by a combination of metal chelation or sulfhydryl group regeneration (28).

The participation of oxidative stress in the nephrotoxicity associated with HgCl₂ was suggested initially by studies that showed that HgCl₂ administration re-

duced renal GSH content and depletion of GSH with diethylmaleate resulted in increased severity of HgCl₂-induced acute renal failure (21, 22). Nevertheless, the role of oxidant-dependent injury is controversial because significant renal damage is present before GSH content is depleted (22) and improvement in nephrotoxicity may occur despite reduction in GSH content (9). Furthermore, lipid peroxide formation may (20, 33) or may not (22) be increased. The most convincing evidence for the role of oxidant injury in this experimental model of renal failure was provided by the studies of Nath et al. (36), who showed that, both in vitro and in vivo, HgCl₂ exposure generated massive amounts of hydrogen peroxide that were quenched by pyruvate and both pyruvate and catalase attenuated mercury-induced cytotoxicity.

Treatment with antioxidants has failed to provide definite evidence for or against a pathogenetic role for ROS in HgCl₂ acute renal failure. Intravenous administration of superoxide dismutase and allopurinol, which scavenges and inhibits the production of superoxide radicals, respectively, failed to protect against

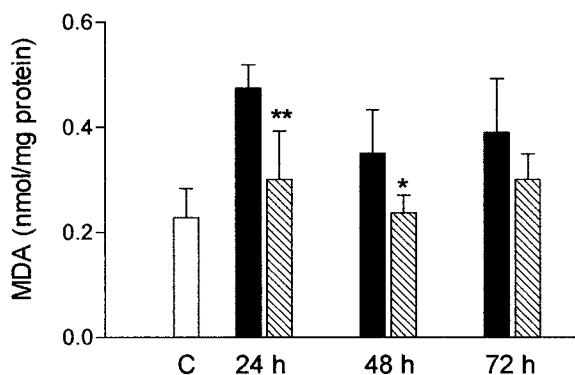


Fig. 9. Renal content of malondialdehyde (MDA) in rats receiving HgCl₂ and melatonin (hatched bars) or vehicle (filled bars). Open bar, control group. Error bars are SD. **P* < 0.05, ***P* < 0.01 vs. the corresponding paired bar.

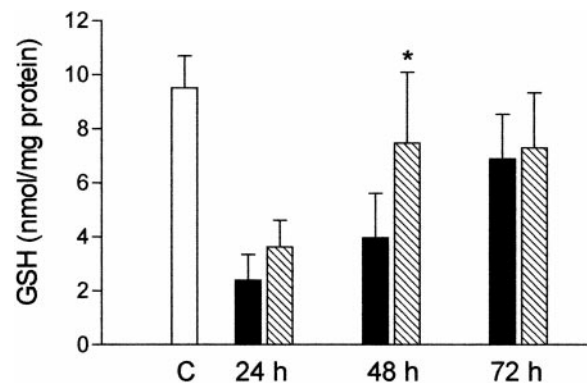


Fig. 10. Renal content of glutathione (GSH) in rats receiving HgCl₂ and melatonin (hatched bars) or vehicle (filled bars). Open bar, control group. Error bars are SD. **P* < 0.05 vs. the corresponding paired bar.

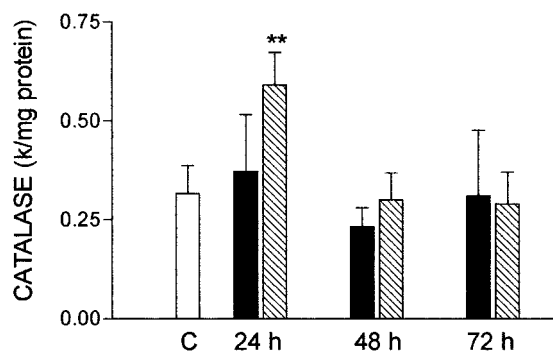


Fig. 11. Renal content of catalase in rats receiving HgCl₂ and melatonin (hatched bars) or vehicle (filled bars). Open bar, control group. Error bars are SD. **P* < 0.01 vs. the corresponding paired bar.

mercuric nephrotoxicity (38). Equally ineffective have been hydroxyl radical scavengers triptophan, *N*-acetyl tryptophan, and ascorbic acid, but, in contrast, dimethylthiourea and dimethyl sulfoxide, both hydroxyl radical scavengers, were beneficial (38). Dietary manipulations aiming for antioxidant effects have also been inconclusive. Andersen et al. (4) reported that vitamin E protected against mercury-induced lipid peroxidation in the liver, but the effects on the kidney were minor. However, diets deficient in selenium and vitamin E aggravate the renal failure induced by HgCl₂ (36). Zinc administration increases the renal concentration of protective antioxidant enzymes and reduces lipid peroxidation that follows mercury nephrotoxicity (18).

Given the lack of unanimity with regard to the role of ROS-mediated injury in HgCl₂-induced acute renal failure, we decided to test the effect of Mel in this experimental model. Mel (*N*-acetyl-5-methoxytryptamine) is naturally produced by the pineal gland from serotonin by a process catalyzed by two enzymes: arylalkylamine *N*-acetyltransferase and hydroxyindole-*O*-methyltransferase. The synthesis and release of Mel in normal conditions is stimulated by darkness and inhibited by light in response to signals originating in the suprachiasmatic nucleus (44). Circulating Mel is rapidly metabolized, conjugated with sulfuric or glucuronic acid, and excreted in the urine.

Large doses of Mel, resulting in blood levels 10,000 times higher than the physiological time peak, have been given without serious side effects (8). Of the several clinical indications proposed for Mel, the best recognized and supported by placebo-controlled trials is the hypnotic effect, but it has been well documented that the drug is a very potent scavenger of hydroxyl and peroxy radicals. Mel antioxidant properties result mainly from electron donation, and its unrestricted crossing of morphophysiological barriers, and easy access to subcellular compartments (42, 43), facilitates the ROS scavenger effect. In addition, Mel may stimulate antioxidant enzymes, i.e., superoxide dismutase, GSH-Px, and glutathione reductase (5, 41, 45). In fact, Mel may be one of the more effective protectors against oxidative damage (8, 41), but such effects require pharmacological doses of the drug. The half-life of intrave-

nous Mel is less than 6 min (27), but the bioavailability of orally administered Mel is variable. Pertinent to this work, oral doses of 1 mg/kg body weight, similar to those used in this investigation, result in serum Mel concentrations that range from 350 to 10,000 times higher than the physiological peak levels 1–2 h after administration and remain stable for 90 min (56). In the rats from the HgCl₂-Mel group, we also found a large variability, but in all cases very high plasma Mel levels 30 min after administration, coinciding with the injection of mercury, that reached peak concentrations after 2 h. Five hours after the administration by gastric gavage, the plasma Mel levels had dropped to ~13% of the maximal values, but they were still elevated. All these values represent pharmacological concentrations because peak nighttime values in the adult rat are 200–300 µg/ml (25). The baseline levels in our rats, before the administration of Mel, between 8 and 9 Am, were 79.4 ± 30.45 µg/ml, not too different from the values reported by others (25).

The present work documents that pretreatment with Mel offers an important protection from HgCl₂-induced acute renal failure. The increment of S_{cr} observed with HgCl₂ was markedly ameliorated in the HgCl₂-Mel group (Fig. 1).

Histological damage was markedly improved by Mel treatment (Table 1 and Fig. 3). As reported by others (55), the intensity of the histological damage was more marked 48 and 72 h after the administration of the toxic agent. At these times, the protection offered by pretreatment with Mel is particularly dramatic (Table 1).

Apoptosis and proliferative reaction are also reduced by Mel (Fig. 6). Apoptosis and the proliferative response were present the first day and were maximal at 72 h, when the last group of rats was killed (Figs. 4 and 5). Similar results were reported by Verstrepen et al. (55), who also found a proliferative response the first day and maximal proliferation 4 days after HgCl₂ administration. To our knowledge, there are no serial studies on the apoptosis induced by HgCl₂. However, apoptosis is known to be induced by mercury in cultured proximal tubular cells (15). In other models of acute renal failure, apoptosis occurs in two phases. The first phase occurs between 12 and 48 h after ischemic or nephrotoxic insult, which probably contributes to the tubular dysfunction associated with the acute renal failure. The second phase occurs later, during the recovery of acute renal failure, and contributes to the remodeling of the damaged tubules (31). Our studies did not extend to the repair stage of the nephrotoxic injury, but we were able to show that the pathogenic phase of apoptosis is improved by Mel.

Apoptosis may be induced by ROS (10), and by the generation of oxygenated derivatives of arachidonic acid, which are potent inducers of apoptosis (11). In addition, intracellular ROS generation results in the expression of genes responsible for apoptosis through the activation of nuclear transcription factors such as NF-κB (47). This process can also be inhibited by Mel (34).

To our knowledge, there are no previous studies of superoxide-producing cells in this experimental condition. Our findings show that the number of superoxide-positive proximal tubular cells increases ~20 times after 24 h of administration of HgCl₂. As shown in Figs. 7 and 8, Mel treatment reduced the number of superoxide-producing cells to normal (control) values. These results may be explained by the stimulation of superoxide dismutase by Mel (5) or by the superoxide scavenger properties of indolyl radicals resulting from ·OH-induced oxidation of Mel (40).

The changes in the renal MDA, GSH content, and GSH-Px and catalase activities were more pronounced on the first day, with subsequent return toward control levels. As reported by others (1), we found that HgCl₂ induced a rapid increment in renal MDA content; lipid peroxidation was significantly reduced by Mel treatment (Fig. 6). HgCl₂ rapidly reacts with SH groups and depletes GSH in tubular cells, as evidenced by the early fall in GSH content of the kidney (Fig. 9). The Mel-treated group also had a significant early decrease in the renal content of GSH, although this effect was less pronounced than in the untreated group. Moreover, 48 h after the nephrotoxic insult, the GSH content in the Mel-treated group had returned to control levels. This rapid improvement may be partially due to increased GSH synthesis by Mel (1). HgCl₂-induced depletion of GSH is probably the cause for the early reduction in GSH-Px activity in this experimental model. GSH-Px activity was partially recovered by day 3, when the values in the HgCl₂-Mel group were not statistically significant in terms of control.

Mercury did not influence basal catalase activity, and this result is in agreement with the results of Nath et al. (36). Pretreatment with Mel produced an increment in catalase, as has been reported with other protective enzymes (5, 41).

The beneficial effects of Mel are only observed if the drug is given at least 30 min before the administration of HgCl₂. If Mel is given in conjunction with or after HgCl₂, the functional and histological damage are not prevented. In these circumstances, Mel treatment does not improve the changes in renal MDA, GSH, GSH-Px, and catalase resulting from mercury-induced ROS generation. Therefore, it appears that successful treatment of the intense oxidative stress generated in HgCl₂ nephrotoxicity requires preexisting availability of highly effective antioxidant mechanisms.

In summary, pretreatment with Mel, administered orally, markedly attenuates the acute nephrotoxicity produced by inorganic mercury. It is likely that the beneficial effects of the drug are related to its antioxidant actions.

Part of this work was presented at the 31st Annual Meeting of the American Society of Nephrology and has appeared in abstract form (*J Am Soc Nephrol* 9: A2995, 1998).

REFERENCES

1. Abe M, Reiter RJ, Orhii PB, Hara M, and Poeggeler B. Inhibitory effect of melatonin on cataract formation in newborn rats: evidence for an antioxidative role for melatonin. *J Pineal Res* 17: 94–100, 1994.
2. Addaya S, Chakravarti K, Basu A, Santra M, Haldar S, and Chatterjee GC. Effects of mercuric chloride on several scavenging enzymes in the rat kidney and influence of vitamin E supplementation. *Acta Vitaminol Enzymol* 6: 103–107, 1984.
3. Aebi HE. Catalase. In: *Methods of Enzymatic Analysis* (3rd ed.), edited by Bergmeyer HU. Weinheim, Germany: Verlag Chemie, 1982, vol. III, p. 271–282.
4. Andersen HR and Andersen O. Effects of dietary alpha-tocopherol and beta-carotene on lipid peroxidation induced by methyl mercuric chloride in mice. *Pharmacol Toxicol* 73: 192–201, 1993.
5. Antolín I, Rodríguez C, Sáinz RM, Mayo JC, Uría H, Kotler ML, Rodríguez-Colunga MJ, Tolvía D, and Menéndez-Pelaez A. Neurohormone melatonin prevents cell damage: effects on gene expression for antioxidant enzymes. *FASEB J* 10: 7882–7890, 1996.
6. Beutler E, Duron O, and Mikus B. Improved method for the determination of blood glutathione (Abstract). *J Lab Clin Med* 16: 882, 1963.
7. Briggs RT, Robinson JM, Karnovsky ML, and Karnovsky MJ. Superoxide production by polymorphonuclear leukocytes. A cytochemical approach. *Histochemistry* 84: 371–378, 1986.
8. Brzezinski A. Melatonin in humans. *N Engl J Med* 336: 1186–1195, 1997.
9. Bohets HH, van Thielon MN, van der Biest I, van Landeghen GH, D'Haese PC, Nouwen EJ, DeBroe ME, and Dierickx PH. Cytotoxicity of mercuric compounds in LLC-PK₁, MDCK and human proximal cells. *Kidney Int* 47: 395–403, 1995.
10. Buttke TM and Sandstrom PA. Oxidative stress as a mediator of apoptosis. *Immunol Today* 15: 7–10, 1994.
11. Christ M, Luu B, Mejia JE, Moosbrugger I, and Bischoff P. Apoptosis induced by oxysterols in murine lymphoma cells and in normal thymocytes. *Immunology* 78: 455–460, 1993.
12. Dahlitz M, Alvarez B, Vignau J, English J, Arendt J, and Parkes JD. Delayed sleep phase syndrome response to melatonin. *Lancet* 337: 1121–1124, 1991.
13. De Lastra CA, Cabeza J, Motilva V, and Martín MJ. Melatonin protects against gastric ischemia-reperfusion injury in rats. *J Pineal Res* 23: 47–52, 1997.
14. DiBowa GF, McDonald FD, Flamenbaum W, Dammin GJ, and Oken DE. Maintenance of renal function in salt loaded rats despite severe tubular necrosis induced by HgCl₂. *Nephron* 8: 205–220, 1971.
15. Dunca-Achanzar KB, Jones JT, Burke MF, Carter DE, and Laird HE II. Inorganic mercury chloride-induced apoptosis in the cultured porcine renal cell line LLC-PK₁. *J Pharmacol Exp Ther* 227: 1726–1732, 1996.
16. Flamenbaum W, Huddleston ML, McNeil JS, and Hamburger RJ. Uranyl nitrate acute renal failure in the rat. Microcirculation and renal hemodynamics studies. *Kidney Int* 6: 408–418, 1974.
17. Flamenbaum W, Kotchen TA, and Oken DE. Effect of renin immunization on mercuric chloride and glycerol-induced renal failure. *Kidney Int* 1: 406–412, 1972.
18. Fukino H. Effects of zinc pretreatment on mercuric chloride-induced lipid peroxidation in the rat kidney. *Toxicol Appl Pharmacol* 73: 395–401, 1984.
19. Guerrero JM, Reiter RJ, Ortiz GG, Pablos MI, Sewerynek E, and Chuang JI. Melatonin prevents increases in neural nitric oxide and c-GMP production after transient brain ischemia and reperfusion in the Mongolian gerbil (*Meriones unguiculatus*). *J Pineal Res* 23: 24–31, 1997.
20. Girardi G and Elias MM. Effectiveness of N-acetylcysteine in protecting against mercuric chloride-induced acute renal failure in the rat. *Kidney Int* 12: 115–121, 1977.
21. Girardi G, Torres MA, and Elias MM. The implication of renal glutathione levels in mercuric chloride nephrotoxicity. *Toxicology* 58: 187–195, 1989.
22. Gstraunthaler G, Pfaller W, and Kotanko P. Glutathione depletion and in vitro lipid peroxidation in mercury or maleate induced acute renal failure. *Biochem Pharmacol* 1: 32: 2969–2972, 1983.

23. Halliwell B and Gutteridge JMC. Oxygen toxicity, oxygen radicals, transition metals and disease. *Biochem J* 219: 1–14, 1984.
24. Huang YL, Chen SL, and Lin TH. Lipid peroxidation in rats administered with mercuric chloride. *Biol Trace Elem Res* 52: 193–206, 1996.
25. Huether G. Melatonin synthesis in the gastrointestinal tract and the impact of nutritional factors on circulating melatonin. *Ann NY Acad Med* 719: 146–158, 1994.
26. Ichikawa I, Kiyama S, and Yoshioka T. Renal antioxidant enzymes: their regulation and function. *Kidney Int* 45: 1–9, 1994.
27. Iguchi H, Kato KI, and Ibayashi Y. Melatonin serum levels and metabolic clearance rate in patients with liver cirrhosis. *J Clin Endocrinol Metab* 54: 1025–1027, 1982.
28. Kleinman JG, McNeil SJ, Schwartz JH, Hamburger RJ, and Flamenbaum W. Effects of dithiothreitol on mercuric chloride and uranyl nitrate-induced acute renal failure in the rat. *Kidney Int* 12: 115–121, 1977.
29. Konturek PC, Konturek SJ, Brzozowski T, Dembinski A, Zembala M, Mytar B, and Hahn EG. Gastroprotective activity of melatonin and its precursor, L-tryptophan, against stress-induced and ischemia-induced lesions is mediated by scavenging of oxygen radicals. *Scan J Gastroenterol* 32: 433–438, 1997.
30. Lawrence RA and Burk RF. Glutathione peroxidase activity in selenium deficient rat liver. *Biochem Biophys Res Commun* 71: 952–958, 1976.
31. Lieberthal W, Koh JS, and Levine JS. Necrosis and apoptosis in acute renal failure. *Semin Nephrol* 18: 505–518, 1998.
32. Lissoni P, Tancini G, Barni S, Paolorossi F, Ardizzoia A, Conti A, and Maestroni G. Treatment of cancer chemotherapy-induced toxicity with the pineal hormone melatonin. *Support Care Cancer* 5: 126–129, 1997.
33. Lund BO, Miller DM, and Woods JS. Mercury-induced H₂O₂ production and lipid peroxidation in vitro in the rat kidney mitochondria. *Biochem Pharmacol* 42: 181–187, 1991.
34. Mohan N, Sadeghi K, Reiter RJ, and Meltz ML. The neurohormone melatonin inhibits cytokine, mitogen and ionizing radiation induced NF-kappa B. *Biochem Mol Biol Int* 37: 1063–1070, 1995.
35. Montilla P, Tunez I, Muñoz MC, Lopez A, and Soria JV. Hyperlipidemic nephropathy induced by adriamycin: effect of melatonin administration. *Nephron* 76: 345–350, 1997.
36. Nath A, Croatt AJ, Likely S, Behrens TW, and Warden D. Renal oxidant injury and oxidant response induced by mercury. *Kidney Int* 50: 1032–1043, 1996.
37. Ohkawa H, Ohishi N, and Yagi K. Assay for lipid peroxides in animal tissues by thiobarbituric acid reaction. *Anal Biochem* 95: 351–358, 1979.
38. Paller MS. Free radical scavengers in mercuric chloride-induced acute renal failure in the rat. *J Lab Clin Med* 105: 459–463, 1985.
39. Paller MS, Manivel JC, Patten M, and Barry M. Prostaglandin protects the kidneys against ischemic and toxic injury by a cellular effect. *Kidney Int* 42: 1345–1354, 1992.
40. Poeggeler B, Saarela S, Reiter RJ, Tan D-X, Chen L-D, Manchester LC, and Barlow-Walden LR. Melatonin—a highly potent endogenous radical scavenger and electron donor: new aspects of the oxidation chemistry of this indole accessed in vitro. *Ann NY Acad Sci* 17: 419–420, 1994.
41. Reiter RJ. The role of the neurohormone melatonin as a buffer against macromolecular oxidative damage. *Neurochem Int* 27: 453–460, 1995.
42. Reiter RJ, Carneiro RC, and Oh CS. Melatonin in relation to cellular antioxidative defense mechanism. *Horm Metab Res* 29: 363–372, 1997.
43. Reiter RJ, Tang I, García JJ, and Muñoz HA. Pharmacological actions of melatonin in oxygen radical pathophysiology. *Life Sci* 60: 2255–2271, 1997.
44. Reppert SM, Weaver DR, Rivkees SA, and Stropa EG. Putative melatonin receptors in a human biological clock. *Science* 242: 78–81, 1988.
45. Rodríguez AB, Nogales G, Ortega E, and Barriga C. Melatonin controls superoxide anion level: modulation of superoxide dismutase activity in ring dove heterophils. *J Pineal Res* 24: 9–14, 1998.
46. Sandstrom PA, Tebbey PW, Van Cleave S, and Buttke TM. Lipid hydroperoxides induce apoptosis in T cells displaying a HIV-associated glutathione peroxidase deficiency. *J Biol Chem* 269: 798–801, 1994.
47. Schreck R, Albermann K, and Baeuerle PA. Nuclear factor kappa B: an oxidative stress-responsive transcription factor of eukaryotic cells. *Free Radic Res Commun* 17: 221–237, 1992.
48. Sewerynek E, Reiter RJ, Melchiorri D, Ortiz GG, and Lewinski A. Oxidative damage, in the liver induced by ischemia-reperfusion: protection by melatonin. *Hepatogastroenterology* 43: 898–905, 1996.
49. Soto H, Mosquera J, Rodríguez-Iturbe B, Henríquez-La Roche C, and Pinto A. Apoptosis in proliferative glomerulonephritis: decreased apoptosis in lupus nephritis. *Nephrol Dial Transplant* 12: 273–280, 1997.
50. Stein JH, Lifschitz MD, and Barnes LD. Currents concepts on the pathophysiology of acute renal failure. *Am J Physiol Renal Physiol* 254: F171–F181, 1978.
51. Tan DX, Chen LD, Poeggeler B, Manchester LC, and Reiter RJ. Melatonin: a potent, endogenous hydroxyl radical scavenger. *Endocrine J* 1: 57–60, 1993.
52. Thiel G, Brunner F, Wunderlich P, Huguennin M, Bienko B, Torhorst J, Peters-Haefeli L, Kirchertz EJ, and Peters G. Protection of rat kidney HgCl₂-induced acute renal failure by induction of high urine flow without renin suppression. *Kidney Int* 10: S191–S200, 1976.
53. Vadiel K, Brunner LJ, and Luke DR. Effects of pentoxifylline in experimental acute renal failure. *Kidney Int* 36: 466–470, 1989.
54. Vanholder R, Laekeman G, Herman A, Saraganda B, Waterloos MA, Kesteloot D, and Lámeire N. The inhibition of thromboxane synthesis has no influence on HgCl₂-induced acute renal failure in the rat. *Nephrol Dial Transplant* 4: 625–631, 1989.
55. Verstrepen WA, Nouwen EJ, Zhu MQ, Ghielli M, and De Broe ME. Time course of growth factor expression in mercuric chloride acute renal failure. *Nephrol Dial Transplant* 10: 1361–1371, 1995.
56. Waldhauser F, Waldhauser M, Lieberman HR, Deng MH, Lynch HJ, and Watman RJ. Bioavailability of oral melatonin in humans. *Neuroendocrinology* 39: 307–313, 1984.
57. Ward RJ, Abiaka C, and Peters TJ. Inflammation and tissue injury: the world of free radicals. *J Nephrol* 7: 89–95, 1994.
58. Weinberg JM, Harding PC, and Humes HD. Mitochondrial bioenergetics during the initiation of mercuric chloride-induced renal injury. *J Biol Chem* 257: 60–67, 1982.
59. Wurtman RJ and Zhdanova I. Improvement of sleep quality by melatonin. *Lancet* 346: 1491, 1995.
60. Yonahan M, Itoh E, Ohabayashi Y, and Uchiyama M. Induction of lipid peroxidation in rats by mercuric chloride. *Res Commun Chem Pathol Pharmacol* 28: 105–112, 1980.
61. Yoshioka T, Ichikawa I, and Fogo A. Reactive oxygen metabolites cause massive, reversible proteinuria and glomerular sieving defect without apparent ultrastructural abnormality. *J Am Soc Nephrol* 2: 902–912, 1991.