

Marilda Mazzali, John Kanellis, Lin Han, Lili Feng, Yi-Yang Xia, Qiang Chen, Duk-Hee Kang, Katherine L. Gordon, Susumu Watanabe, Takahiko Nakagawa, Hui Y. Lan and Richard J. Johnson

Am J Physiol Renal Physiol 282:991-997, 2002. First published Jan 2, 2002;
doi:10.1152/ajprenal.00283.2001

You might find this additional information useful...

This article has been cited by 46 other HighWire hosted articles, the first 5 are:

Serum uric acid levels predict the development of albuminuria over 6 years in patients with type 1 diabetes: Findings from the Coronary Artery Calcification in Type 1 Diabetes study

D. I. Jalal, C. J. Rivard, R. J. Johnson, D. M. Maahs, K. McFann, M. Rewers and J. K. Snell-Bergeon

Nephrol. Dial. Transplant., January 11, 2010; 0 (2010): gfp740v1-gfp740.

[\[Abstract\]](#) [\[Full Text\]](#) [\[PDF\]](#)

A comprehensive study of cardiovascular risk factors, cardiac function and vascular disease in children with chronic renal failure

C. Rinat, R. Becker-Cohen, A. Nir, S. Feinstein, D. Shemesh, N. Algur, E. Ben Shalom, B. Farber and Y. Frishberg

Nephrol. Dial. Transplant., November 23, 2009; 0 (2009): gfp570v1-gfp570.

[\[Abstract\]](#) [\[Full Text\]](#) [\[PDF\]](#)

Uric acid is associated with the rate of residual renal function decline in peritoneal dialysis patients

J. T. Park, D. K. Kim, T. I. Chang, H. W. Kim, J. H. Chang, S. Y. Park, E. Kim, S.-W. Kang, D.-S. Han and T.-H. Yoo

Nephrol. Dial. Transplant., November 1, 2009; 24 (11): 3520-3525.

[\[Abstract\]](#) [\[Full Text\]](#) [\[PDF\]](#)

A novel role for uric acid in acute kidney injury associated with tumour lysis syndrome

M. Shimada, R. J. Johnson, W. S. May Jr, V. Lingegowda, P. Sood, T. Nakagawa, Q. C. Van, B. Dass and A. A. Ejaz

Nephrol. Dial. Transplant., October 1, 2009; 24 (10): 2960-2964.

[\[Full Text\]](#) [\[PDF\]](#)

Moderate-to-severe early-onset hyperuricaemia: a prognostic marker of long-term kidney transplant outcome

S. I. Min, I. J. Yun, J. M. Kang, Y. J. Park, S. K. Min, C. Ahn, S. J. Kim and J. Ha

Nephrol. Dial. Transplant., August 1, 2009; 24 (8): 2584-2590.

[\[Abstract\]](#) [\[Full Text\]](#) [\[PDF\]](#)

Updated information and services including high-resolution figures, can be found at:

<http://ajprenal.physiology.org/cgi/content/full/282/6/F991>

Additional material and information about *AJP - Renal Physiology* can be found at:

<http://www.the-aps.org/publications/ajprenal>

This information is current as of February 10, 2010 .

Hyperuricemia induces a primary renal arteriolopathy in rats by a blood pressure-independent mechanism

MARILDA MAZZALI, JOHN KANELIS, LIN HAN, LILI FENG, YI-YANG XIA, QIANG CHEN, DUK-HEE KANG, KATHERINE L. GORDON, SUSUMU WATANABE, TAKAHIKO NAKAGAWA, HUI Y. LAN, AND RICHARD J. JOHNSON

Division of Nephrology, Baylor College of Medicine, Houston, Texas 77030

Received 21 March 2001; accepted in final form 4 December 2001

Mazzali, Marilda, John Kanellis, Lin Han, Lili Feng, Yi-Yang Xia, Qiang Chen, Duk-Hee Kang, Katherine L. Gordon, Susumu Watanabe, Takahiko Nakagawa, Hui Y. Lan, and Richard J. Johnson. Hyperuricemia induces a primary renal arteriolopathy in rats by a blood pressure-independent mechanism. *Am J Physiol Renal Physiol* 282: F991–F997, 2002. First published January 2, 2002; 10.1152/ajprenal.00283.2001.—Hyperuricemia is associated with hypertension and vascular disease, but whether this represents a causal relationship or an epiphenomenon remains unknown. We recently reported a model of mild hyperuricemia in rats that results in increased blood pressure and mild renal fibrosis. In this study, we examined the effect of hyperuricemia on the renal vasculature. Rats fed 2% oxonic acid and a low-salt diet for 7 wk developed mild hyperuricemia (1.8 vs. 1.4 mg/dl, $P < 0.05$), hypertension [147 vs. 127 mmHg systolic blood pressure (SBP), $P < 0.05$], and afferent arteriolar thickening, with a 35% increase in medial area ($P < 0.05$). Allopurinol or benzydaronone prevented the hyperuricemia, hypertension, and arteriolopathy. Hydrochlorothiazide treatment did not prevent the hyperuricemia or arteriolopathy despite controlling blood pressure. In contrast, the arteriolopathy and hypertension were prevented by both enalapril and losartan. Uric acid also directly stimulated vascular smooth muscle cell proliferation in vitro, and this was partially inhibited by losartan. Thus hyperuricemia induces a renal arteriolopathy in rats that is blood pressure independent and involves the renin-angiotensin system.

uric acid; hypertension; angiotensin II

THE PRESENCE OF AN ELEVATED serum uric acid is associated with hypertension and cardiovascular disease (reviewed in Ref. 22). Despite the strength of the association and the ease in treating this condition, it remains unknown whether elevated uric acid has a pathogenic role in cardiovascular disease or whether it simply represents a “marker” for other cardiovascular risk factors with which it is commonly associated, such as hypertension, renal disease, obesity, insulin resistance, and diuretic use (22). Epidemiological studies have been unable to resolve this issue (1, 5, 8), and experimental studies have been thwarted by the lack of an animal model of mild hyperuricemia that mimics

the human condition, a paucity of cell culture studies, and the absence of a tenable mechanism by which uric acid could cause cardiovascular disease or hypertension.

Recently, our group developed an animal model of mild hyperuricemia by feeding oxonic acid to rats (14, 15). Oxonic acid is an inhibitor of uricase, a hepatic enzyme present in most mammals that degrades uric acid to allantoin. Humans and the great apes lack this enzyme because of several mutations that occurred during early hominoid evolution 8–20 million years ago (29). Rats fed low doses of oxonic acid developed a mild increase in serum uric acid without intrarenal crystal deposition or acute renal failure, which occurred in previous models (14, 15). Hence, this model was considered ideal for studying the effects of mild hyperuricemia on cardiovascular disease.

An unexpected finding in this model was the observation that mild hyperuricemia induced a blood pressure elevation after several weeks (14). Systolic blood pressure (SBP) directly correlated with serum uric acid levels, and a 1 mg/dl change in uric acid was associated with a 30- to 40-mmHg increase in blood pressure. The effect of hyperuricemia on blood pressure was particularly evident in the presence of a sodium-restricted diet, but an increase in blood pressure was also shown under normal-salt-diet conditions. Evidence that the increase in blood pressure was due to the uric acid was demonstrated by preventing the increase in uric acid in oxonic acid-treated rats by administering allopurinol (a xanthine oxidase inhibitor) or benzydaronone (a uricosuric agent). Both drugs prevented the development of hyperuricemia and the increase in blood pressure (14).

Further studies clarified the mechanism by which uric acid induced the blood pressure elevation (15). Hyperuricemic rats had elevated juxtaglomerular renin expression as well as a decrease in nitric oxide synthase-1 (NOS-1) in the macula densa. Macula densa generates nitric oxide, which has an important role in modulating afferent arteriolar tone and tubuloglomerular feedback (28). Stimulation of renin and

Address for reprint requests and other correspondence: R. J. Johnson, Div. of Nephrology, Alkek 5th Floor Renal Research Laboratory, 1 Baylor Plaza, Baylor College of Medicine, Houston, TX 77030 (E-mail: rjohnson@bcm.tmc.edu).

The costs of publication of this article were defrayed in part by the payment of page charges. The article must therefore be hereby marked “advertisement” in accordance with 18 U.S.C. Section 1734 solely to indicate this fact.

inhibition of macula densa NOS-1 would be expected to result in increased renal vascular resistance and increased proximal tubule sodium reabsorption, which is compatible with reports in humans that hyperuricemia is associated with increased plasma renin activity (23), increased renal vascular resistance (16), and increased sodium reabsorption in the proximal tubules (4).

We now report another effect of uric acid in our model, which is to induce a medial vascular thickening of the preglomerular vessels in the kidney. We further show that the mechanism of the afferent arteriopathy is independent of blood pressure and that it is partially dependent on angiotensin II.

METHODS

Experimental Design

Male Sprague-Dawley rats (200–250 g; Simonsen Laboratories, Gilroy, CA) were housed in individual cages, and blood pressure and serum uric acid were measured at multiple time points. After a week of adaptation to the blood pressure measurements, rats were divided in groups, matched according to SBP, body weight, and serum uric acid levels, and followed for 7 wk.

Experiment I. To analyze the effect of hyperuricemia on blood pressure and renal vasculature, rats were divided into groups as follows. Control animals ($n = 5$) were administered a low-salt diet (0.125% NaCl). Hyperuricemia rats ($n = 5$) were fed a low-salt diet plus 2% oxonic acid. Allopurinol rats ($n = 6$) were administered a low-salt and oxonic acid diet with allopurinol (150 mg/l) in the drinking water. Benzydaronone rats ($n = 5$) were administered a low-salt and oxonic acid diet with benzydaronone (10 mg·kg⁻¹·day⁻¹) in the drinking water.

Experiment II. To evaluate the effect of blood pressure control on vascular changes, two additional groups of rats were included. Results were compared with control and hyperuricemic rats. Hydrochlorothiazide (HCTZ) rats ($n = 5$) were fed a low-salt and oxonic acid diet with HCTZ (3 mg·kg⁻¹·day⁻¹) in the drinking water. Enalapril rats ($n = 6$) were fed a low-salt and oxonic acid diet with enalapril (1 mg·kg⁻¹·day⁻¹) in the drinking water.

Experiment III. To analyze the role of the renin-angiotensin system in the presence of normal-salt conditions, we studied four additional groups. Normal-salt controls were fed a normal-salt (0.26% NaCl) diet. Hyperuricemia rats were fed a normal-salt and oxonic acid diet. Enalapril treatment rats were fed a normal-salt and oxonic acid diet with enalapril (1 mg·kg⁻¹·day⁻¹) in the drinking water. Losartan treatment rats were fed a normal-salt and oxonic acid diet with losartan (10 mg·kg⁻¹·day⁻¹) in the drinking water.

Drugs

Allopurinol (100 mg), benzydaronone (50 mg; Sanofi), enalapril (5 mg; Merck), HCTZ (50 mg), and losartan (50 mg; Merck) tablets were diluted in the drinking water. The amount of drug added to the drinking water was adjusted every 2 days according to body weight and water intake to provide doses (in mg·kg⁻¹·day⁻¹) of 3 HCTZ, 1 enalapril, 10 losartan, and 10 benzydaronone. In the benzydaronone group, the daily dose was increased to 15 mg·kg⁻¹·day⁻¹ at 2 wk because the original dose was insufficient to lower the uric acid levels.

Evaluation

In all studies, SBP was measured by using a tail-cuff sphygmomanometer with an automated system and photo-

electric sensor (IITC). All animals were preconditioned for blood pressure measurements 1 wk before each experiment. Serum uric acid was measured by the carbonate phosphotungstate method (13). Serum blood urea nitrogen was measured by using a standard kit (Sigma).

Renal Histology

Renal biopsies were fixed in methyl Carnoy's solution and embedded in paraffin. Sections of methyl Carnoy's fixed tissue (4 μm) were stained with periodic acid-Schiff (PAS) reagent or analyzed by indirect immunoperoxidase staining with the primary antibodies monoclonal mouse anti-vimentin (DAKO) and monoclonal mouse anti-α-smooth muscle actin (Sigma).

Quantification of Morphology

All quantifications were performed in a blinded fashion. Only vessels adjacent to glomeruli in the outer cortex were selected. Afferent arterioles were distinguished from efferent arterioles by the presence of an internal elastic lamina and by thin, flattened endothelial cells (7). By using immersion-fixed tissue, afferent arteriolar wall thickness was measured by computer image analysis. For each arteriole, the outline of the vessel and its internal lumen (excluding the endothelium) were generated by using computer analysis to calculate the total medial area (outline-inline) in a minimum of 12 arterioles/biopsy. Vessels that were cross-sectioned or not sectioned transversally, providing an asymmetrical wall, were excluded from the present study. Although perfusion-fixed tissue is often preferred for morphometric measurements (17), immersion-fixed tissue is acceptable for measuring medial thickness (24), and comparisons are also valid because all samples were treated with the same method. The media-to-lumen ratio was calculated by the outline-inline relationship. A tubulointerstitial injury score (0–5) was based on the degree of tubular injury observed by using light microscopy with PAS-stained tissue as previously described (14).

Smooth Muscle Cell Culture

Primary rat aortic vascular smooth muscle cells (SMCs) from passages 8–20 were cultured in DMEM supplemented with 5% fetal bovine serum, penicillin (100 U/ml), and streptomycin (100 μg/ml) (9). Cells were incubated at 37°C in a humidified atmosphere of 95% air-5% CO₂. The medium was changed every 3 days, and cells were subcultured by treatment with 0.05% trypsin-0.02% EDTA solution.

Proliferation Assay

Cells were growth arrested for 24 h in serum-free media (DMEM). Cells were suspended in DMEM at a concentration of 5×10^4 cells/ml, and 200 μl were added to a 96-well tissue culture plate with uric acid (3 mg/dl; Sigma) in the presence or absence of losartan (0.1 and 0.5 μM). At 48 h, cell proliferation was assessed by using a 3-(4,5-dimethylthiazol-2-yl)-2,5-diphenyltetrazolium bromide assay (Promega) and expressed as cell counts per well. For each experiment, 8–16 wells/group were used.

Statistical Analysis

Values are expressed as means ± SD. Differences between groups were evaluated by ANOVA with appropriate correction for multiple comparisons (Bonferroni and Dunn). The relationship between variables was assessed by Pearson correlation analysis. Significance was defined as $P < 0.05$.

RESULTS

Hyperuricemic Rats Develop Hypertension and an Afferent Arteriopathy

The administration of 2% oxonic acid to rats on a low-salt (0.125% NaCl) diet resulted in mild hyperuricemia compared with control rats on a low-salt diet alone (1.84 vs. 1.39 mg/dl, 7 wk, oxonic acid diet vs. control, $P < 0.01$) in association with the development of mild hypertension (SBP 147 ± 8 vs. 127 ± 5 mmHg, 7 wk, oxonic acid vs. control, $P < 0.01$). Both hyperuricemia and elevation in blood pressure were prevented by the administration of either allopurinol (a xanthine oxidase inhibitor) or benziodarone (a uricosuric agent; Table 1). Renal function, as assessed by blood urea nitrogen levels, was slightly reduced in the hyperuricemic rats, and this reduction was also prevented by either allopurinol or benziodarone (Table 1).

Light microscopy (PAS staining) of the kidney appeared unremarkable in hyperuricemic rats, although there were minor changes consisting of tubular dilatation and atrophy in $<10\%$ of the renal cortex (14). However, on careful examination, one could observe thickening of the afferent arterioles and some interlobular arteries, with sparing of the larger vessels. The thickening of the afferent arterioles was universal, and rare afferent arterioles displayed hyalinosis (Fig. 1, A–C). Afferent arterioles from hyperuricemic rats showed a relative increase in immunostaining for α -smooth muscle actin (Fig. 1F) compared with control rats (Fig. 1D). The interlobular arteries of hyperuricemic rats also showed a qualitative increase in vimentin staining (Fig. 1G) compared with controls (Fig. 1E). By using computer image analysis, a 35% increase in afferent arteriolar cross-sectional surface area was documented in hyperuricemic vs. control rats ($P < 0.05$). An increase in the arteriolar medial-to-lumen ratio was also present (Table 1). The arteriolar thickening and increased arteriolar medial-to-lumen ratio were not observed in low-salt-diet controls or in low-salt- and oxonic acid-treated animals that received allopurinol or benziodarone (Table 1). The afferent arteriolar thickness correlated with both SBP ($r^2 = 0.52$, $P < 0.05$) and serum uric acid levels ($r^2 = 0.34$, $P < 0.05$; Fig. 1, H and I).

Hyperuricemia-Induced Arteriopathy Is a Primary Event and Is Not Secondary to Hypertension

Arteriolar disease in hypertension is often considered a vascular response to the increased blood pres-

sure (26). Therefore, we examined the effect of controlling blood pressure on the development of the arteriopathy in oxonic acid-treated rats. Rats were placed on a low-salt and oxonic acid diet and treated with HCTZ ($3 \text{ mg} \cdot \text{kg}^{-1} \cdot \text{day}^{-1}$) or with the angiotensin-converting enzyme (ACE) inhibitor enalapril ($1 \text{ mg} \cdot \text{kg}^{-1} \cdot \text{day}^{-1}$) to maintain blood pressure in the normal range during the entire study period.

Both antihypertensive agents prevented the development of hypertension in the oxonic acid-treated rats (Fig. 2A). As expected, uric acid levels were slightly increased (although not significantly) with HCTZ treatment (Table 2). Despite maintaining normal blood pressure, the development of the arteriolar lesions was not prevented by HCTZ therapy (Fig. 2B). In these rats, the arteriolar medial thickness was not different from the oxonic acid-treated rats. However, the medial-to-lumen ratios were partially but significantly reduced. In contrast, enalapril significantly reduced the arteriolar thickening and the increase in the medial-to-lumen ratio in hyperuricemic rats, and the values were similar to normouricemic controls (Fig. 2B, Table 2).

The previous experiments were performed under low-salt-diet conditions, because the effect of hyperuricemia on blood pressure is most pronounced under these dietary conditions (14). Therefore, we performed additional experiments in the presence of a normal-salt diet. Rats were treated with normal salt (0.26% NaCl), normal salt and oxonic acid, or normal salt and oxonic acid with either losartan ($10 \text{ mg} \cdot \text{kg}^{-1} \cdot \text{day}^{-1}$) or enalapril ($1 \text{ mg} \cdot \text{kg}^{-1} \cdot \text{day}^{-1}$) for 7 wk. Oxonic acid-treated rats developed hyperuricemia, hypertension, and the renal afferent arteriopathy (Table 3). Both enalapril and losartan prevented the increase in blood pressure induced by oxonic acid (Fig. 3A), and both prevented the arteriopathy (Table 3). Interestingly, uric acid levels tended to be lower in the losartan group compared with untreated controls ($P = 0.054$, Table 3), which likely relates to the fact that losartan has some uricosuric activity (3, 20).

Uric Acid Stimulates SMC Proliferation in Vascular SMCs: Role of Angiotensin II

The observation that hyperuricemic rats develop an arteriopathy by means of a blood pressure-independent effect suggested that uric acid might be acting directly on the vascular SMCs. SMCs incubated with uric acid (3 mg/dl) for 48 h showed a marked increase in cell proliferation (Fig. 3). Proliferation was not observed with oxonic acid (3 mg/dl; data not shown). The

Table 1. *Hyperuricemia is associated with afferent arteriopathy*

	Control*	Oxonic Acid (2%)	Allopurinol, 150 mg/l	Benziodarone, 15 mg/kg
Serum uric acid, mg/dl	1.39 ± 0.07	$1.84 \pm 0.21^\dagger$	1.32 ± 0.06	1.40 ± 0.13
Systolic blood pressure, mmHg	126.8 ± 4.9	$146.9 \pm 8.5^\dagger$	119.3 ± 5.6	127.8 ± 6.3
Arteriolar area, μm^2	128.1 ± 13.4	$170.7 \pm 20.1^\dagger$	127.8 ± 4.9	139.1 ± 8.6
Media-to-lumen ratio	3.07 ± 0.24	$4.28 \pm 0.29^\dagger$	3.10 ± 0.37	3.15 ± 0.17
Blood urea nitrogen, mg/dl	15.6 ± 3.8	$20.5 \pm 3.8^\dagger$	11.8 ± 1.8	12.2 ± 3.5

*Low-salt diet. $^\dagger P < 0.05$ vs. other groups.

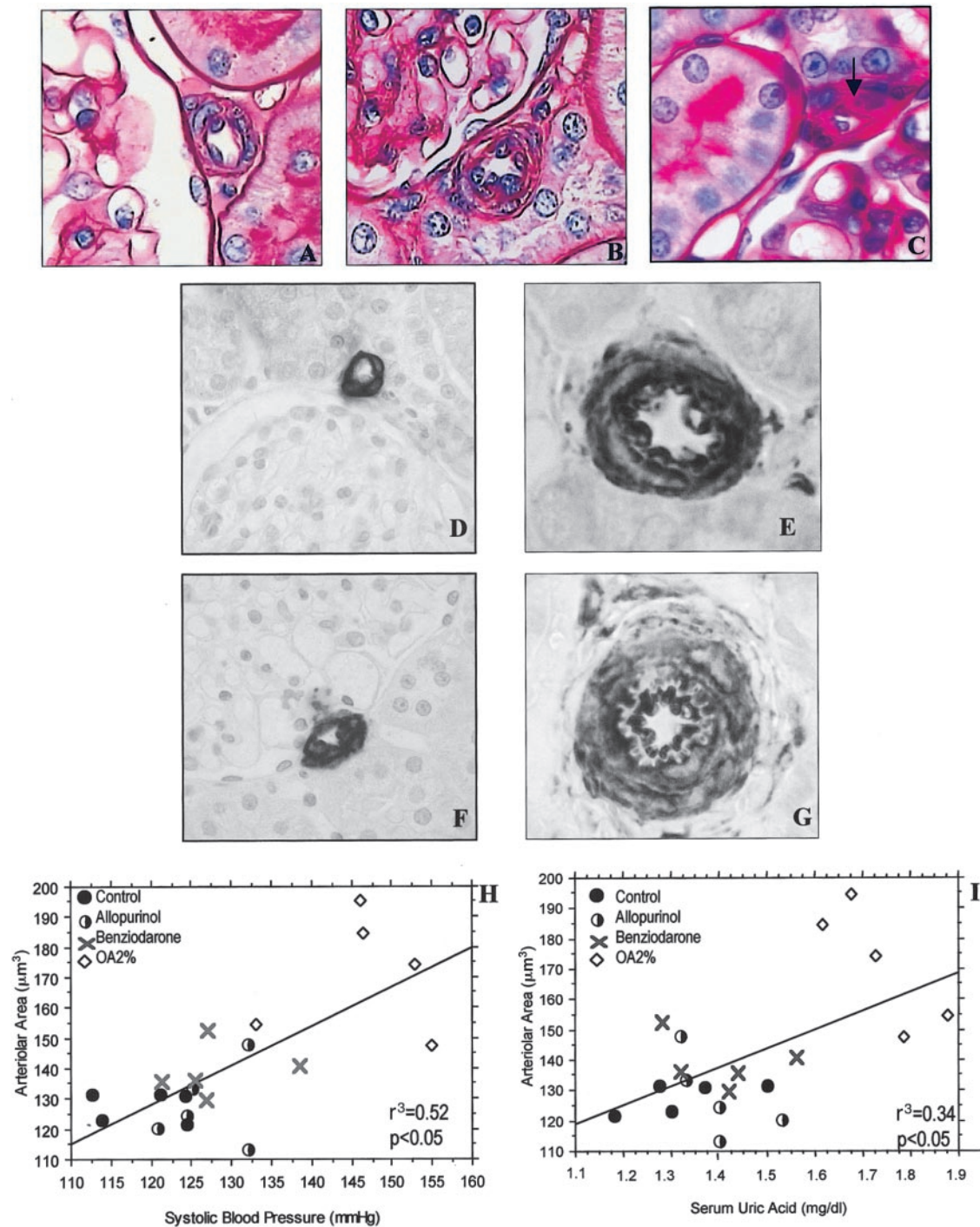


Fig. 1. Hyperuricemia is associated with small-vessel disease in the kidney. Hyperuricemia was associated with an increase in the afferent arteriolar wall thickness in hyperuricemic rats (B) compared with normouricemic controls (A). C: occasional arterioles in hyperuricemic rats showed hyalinosis. There was also a qualitative increase in α -smooth actin staining in arterioles (F) and of vimentin in intralobular arteries (G) in hyperuricemic rats vs. control rats (D and E, respectively). The severity of arteriolar thickness correlated with both systolic blood pressure levels (H) and serum uric acid (I). ●, Control; ◊, 2% oxonic acid (OA); ×, benziodarone; ○, allopurinol. A–C: periodic acid-Schiff staining, $\times 1,000$. E, G: vimentin, $\times 1,000$. F: α -actin staining, $\times 1,000$.

cell proliferation could be partially blocked by losartan at both 0.1 and 0.5 μM (Fig. 3). A similar inhibition in cell proliferation in response to uric acid could be shown with irbesartan at the same concentrations (data not shown).

DISCUSSION

Hyperuricemia is associated with hypertension and cardiovascular disease, but a pathogenic mechanism to explain this association has been lacking. Recently, we

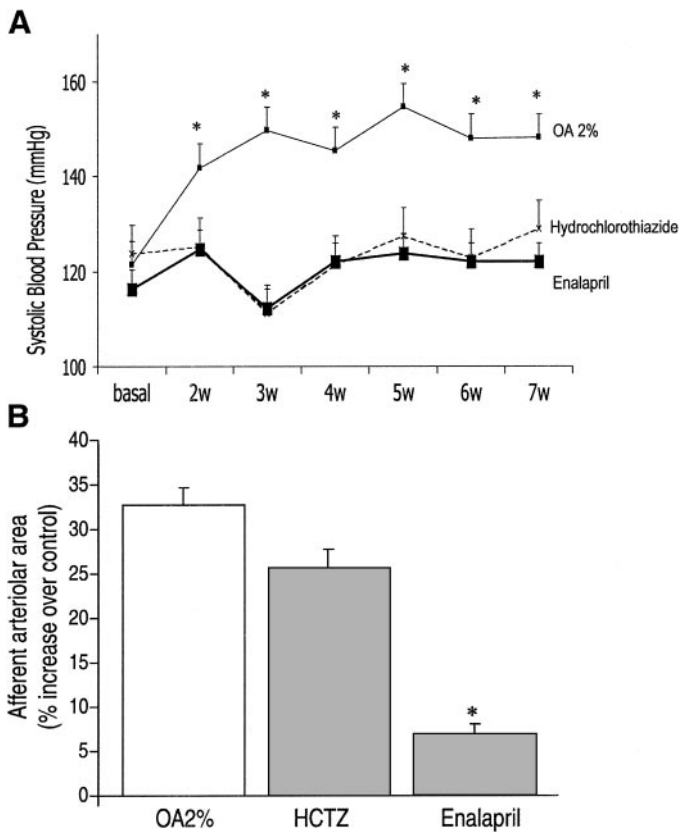


Fig. 2. Arteriolar thickness is independent of blood pressure control in hyperuricemic rats. A: hyperuricemic rats develop modest hypertension, and this can be prevented by treatment with either hydrochlorothiazide or enalapril. B: despite similar blood pressure control, afferent arteriolar thickening was only prevented by enalapril. HCTZ, hydrochlorothiazide; w, week(s). **P* < 0.05 vs. other groups.

reported that mild hyperuricemia induced by the uricase inhibitor oxonic acid raises blood pressure by means of a crystal-independent mechanism that involves activation of the renin-angiotensin system and inhibition of NOS-1 in macula densa (14).

In this study, we demonstrate a new finding that hyperuricemia is associated with a primary arteriopathy of the preglomerular renal vasculature. The arteriopathy was universally present in afferent arterioles and consisted of thickening of media, suggesting hypertrophic vascular remodeling (17). In rare arterioles, hyalinosis was also present, and interlobular arteries demonstrated a qualitative increase in vimentin staining. The increased arteriolar thickening was confirmed by computer image analysis performed un-

der blinded conditions. The arteriopathy was not observed in oxonic acid-treated rats in which hyperuricemia was prevented by the administration of allopurinol (a xanthine oxidase inhibitor) or with benziodarone (a uricosuric agent). This suggests that the arteriopathy was not secondary to the oxonic acid but rather was mediated by the uric acid. This was also consistent with the finding that the uric acid levels in individual animals correlated with the severity of the arteriopathy and also with the finding that uric acid, but not oxonic acid, stimulates SMC proliferation in vitro.

Thickening of the afferent arterioles with hyalinosis is commonly referred to as arteriosclerosis and is observed in 98% of biopsies of individuals with benign essential hypertension (26). Although Goldblatt (11) had postulated that primary arteriolar disease could underlie the pathogenesis of essential hypertension, he had no mechanism by which it could develop, and subsequent studies by Perera (19) led to the conclusion that the arteriopathy might be a secondary consequence.

Therefore, we investigated whether the increased blood pressure in the hyperuricemic rats could be responsible for the afferent arteriopathy. Rats were treated with an agent that blocks the renin-angiotensin system (enalapril) and then compared with those treated with a diuretic that does not (HCTZ). We decided to examine the role of HCTZ in the vascular disease induced by uric acid because hyperuricemia is a complication of diuretic therapy and has been implicated as a risk factor for cardiovascular events in thiazide-treated patients (10). The main finding was that both enalapril and HCTZ were able to reduce blood pressure, but only enalapril significantly inhibited the arteriopathy. Although it is known that the tail-cuff method is not as accurate as continuous telemetry in the measurement of blood pressure (12), these studies provide evidence that control of blood pressure alone is not enough to prevent the medial wall thickening of the afferent arteriole. Interestingly, although HCTZ did not prevent arteriolar thickening, it did partially reduce the medial-to-lumen ratio. This might be explained by the ability of HCTZ to induce vascular dilation.

In contrast to the inability of HCTZ to affect medial thickening, the arteriopathy was significantly attenuated by the ACE inhibitor enalapril. The observation that ACE inhibitors can prevent arteriopathy is consistent with other studies that suggest that this group of drugs can reduce SMC proliferation and collagen

Table 2. Increase in arteriolar area is independent of blood pressure control

	Control*	Oxonic Acid (2%)	Enalapril	Hydrochlorothiazide
Serum uric acid, mg/dl	1.39 ± 0.07	1.84 ± 0.21†	1.86 ± 0.21†	1.94 ± 0.07†
Systolic blood pressure, mmHg	126.8 ± 4.9	146.9 ± 8.5†	122.5 ± 4.5‡	126.0 ± 6.8‡
Tubulointerstitial score	0.11 ± 0.09	0.24 ± 0.06†	0.14 ± 0.09	0.28 ± 0.10‡§
Arteriolar area, μm ²	128.1 ± 13.4	170.7 ± 20.1‡§	137.1 ± 16.5	161.1 ± 6.9‡§
Media-to-lumen ratio	3.07 ± 0.24	4.28 ± 0.29‡§	3.08 ± 0.17‡	3.57 ± 0.24‡§

*Low-salt diet. †*P* < 0.05 vs. control. ‡*P* < 0.05 vs. oxonic acid. §*P* < 0.05 vs. enalapril. All ANOVA and Fisher's protected least significant difference tests.

Table 3. *Renin-angiotensin blockade prevents development of afferent arteriolopathy*

	Control*	Normal Salt + Oxonic Acid (2%)	Normal Salt-Oxonic Acid + Enalapril	Normal Salt-Oxonic Acid + Losartan
Systolic blood pressure, mmHg	133.4 ± 5.4	149.2 ± 7.9†	125.2 ± 2.0	121.0 ± 3.8
Serum uric acid, mg/dl	1.34 ± 0.05	1.91 ± 0.35†	1.94 ± 0.08	1.64 ± 0.08
Tubulointerstitial score	0.06 ± 0.05	0.25 ± 0.08†	0.10 ± 0.09	0.11 ± 0.09
Arteriolar area, μm^2	134.8 ± 10.9	152.2 ± 8.1†	126.3 ± 8.5	130.4 ± 5.4
Media-to-lumen ratio	2.9 ± 0.16	3.5 ± 0.29†	3.01 ± 0.21	2.80 ± 0.11
Blood urea nitrogen, mg/dl	14.6 ± 2.5	14.6 ± 1.5	11.2 ± 4.2	12.9 ± 3.2

*Normal salt. † $P < 0.05$ vs. other groups.

synthesis independently of blood pressure (18, 25). Because a low-salt diet will activate the renin-angiotensin system, we also examined the effect of enalapril and losartan on the arteriolopathy induced by oxonic acid in the setting of a normal-salt diet. We again confirmed that the vasculopathy induced by oxonic acid could be blocked by enalapril. In addition, losartan, which is an angiotensin II type 1 (AT_1) receptor antagonist, also blocked the arteriolopathy, suggesting that the AT_1 receptor may be important in the vascular remodeling, as has been observed in other systems (6). However, losartan's effect could be mediated in part by its known uricosuric action (20), because uric acid levels tended to be lower in the losartan-treated rats. The ability of losartan to lower uric acid is unique to losartan and is not observed in other AT_1 receptor antagonists (3). Further studies will be required to determine whether losartan provides any superior effect over other means for blocking the renin-angiotensin system in hyperuricemic rats.

The observation that the arteriolopathy occurred independently of blood pressure led us to examine the direct effect of uric acid on rat vascular SMCs. Rao et al. (21) had previously reported that uric acid could induce platelet-derived growth factor A-chain expression and cell proliferation in vascular SMCs, and we also confirmed the proliferative effect of uric acid. Consistent with the *in vivo* results, we also found that the

SMC proliferation in response to uric acid *in vitro* could be partially blocked by losartan.

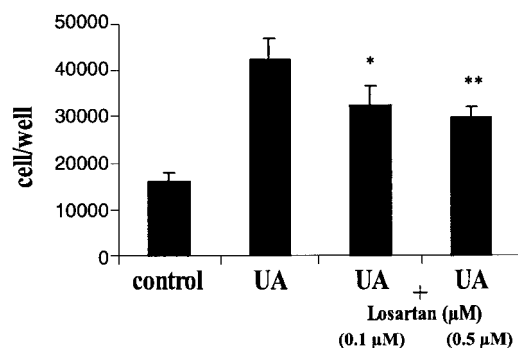
Recently, we have found that hyperuricemia (induced by oxonic acid administration) also exacerbates the microvascular and tubulointerstitial disease induced by cyclosporine (15). Rats administered oxonic acid and cyclosporin showed higher serum uric acid levels in association with worse afferent arteriolar lesions and more severe tubulointerstitial disease (15). Like the uric acid model, the arteriolopathy in experimental cyclosporin nephropathy can also be prevented by enalapril or losartan (2).

The observation that experimental hyperuricemia can cause renal microvascular disease that is not blocked by thiazide therapy despite control of blood pressure may be clinically relevant. Indeed, despite the great benefit of diuretics in lowering hypertension-associated mortality, there is some evidence that the protection is less than expected for the degree of blood pressure control (27). Even in situations of treated hypertension, cardiovascular events continue, and this correlates with the degree of hyperuricemia present (1). A recent analysis of the Systolic Hypertension in the Elderly Program trial found that those individuals who developed hyperuricemia on chlorthalidone therapy continued to have cardiovascular events similar to untreated patients (10). We suggest that one mechanism by which thiazide-induced hyperuricemia may counter the beneficial effect of thiazides to lower blood pressure could be by means of the stimulation of SMC proliferation and the development of vascular disease.

In summary, we have demonstrated that hyperuricemia induces a primary arteriolopathy of the afferent arteriole in rats. An important caveat is that one must be careful in extrapolating animal models to the human condition. Nevertheless, the observation that hyperuricemia results in an afferent arteriolopathy in the rat may provide one of the mechanisms long sought by Goldblatt (11) to account for the primary renal microvascular disease that he postulated underlies the pathogenesis of hypertension. We suggest that further studies on the mechanisms by which uric acid influences cardiovascular disease are warranted.

The suggestions and technical help of Katherine L. Gordon and Yi-Yang Xia are greatly appreciated.

This work was supported by an unrestricted grant from Merck, Inc. M. Mazzali was supported by the postdoctoral program of the



* $P > 0.05$, ** $P < 0.01$ UA vs UA+Losartan(0.1, 0.5 μM)

Fig. 3. Uric acid (UA)-induced smooth muscle cell proliferation is partially dependent on angiotensin II. Rat vascular smooth muscle cells were incubated with UA (3 mg/dl) for 48 h, and cell proliferation was measured by the 3-(4,5-dimethylthiazol-2-yl)-2,5-diphenyltetrazolium bromide assay. UA induced marked cell proliferation, which was partially inhibited by losartan (0.1 and 0.5 μM).

Fundação de Amparo a Pesquisa do Estado de São Paulo, São Paulo, Brazil.

REFERENCES

1. Alderman MH, Cohen H, Madhavan S, and Kivlighn S. Serum uric acid and cardiovascular events in successfully treated hypertensive patients. *Hypertension* 34: 144–150, 1999.
2. Burdmann EA, Andoh TF, Nast CC, Evan A, Connors BA, Coffman TM, Lindsley J, and Bennett WM. Prevention of experimental cyclosporine-induced interstitial fibrosis by losartan and enalapril. *Am J Physiol Renal Physiol* 269: F491–F499, 1995.
3. Burnier M, Roch-Ramel F, and Brunner HR. Renal effects of angiotensin II receptor blockade in normotensive subjects. *Kidney Int* 49: 1787–1790, 1996.
4. Cappuccio F, Iacone R, and Strazzullo P. Serum uric acid, and proximal sodium excretion: an independent association in man (the Olivetti study). *J Hypertens* 9: S280–S281, 1991.
5. Culleton BF, Larson MG, Kannel WB, and Levy D. Serum uric acid and risk for cardiovascular disease and death: the Framingham Study. *Ann Intern Med* 131: 7–13, 1999.
6. Dzau VJ. Tissue angiotensin and pathobiology of vascular disease. A unifying hypothesis. *Hypertension* 37: 1047–1052, 2001.
7. Elger M, Sakai T, and Kriz W. The vascular pole of the renal glomerulus of rat. *Adv Anat Embryol Cell Biol* 139: 1–98, 1998.
8. Fang J and Alderman MH. Serum uric acid and cardiovascular mortality. The NHANES I Epidemiologic Follow-up Study, 1971–1992. *JAMA* 283: 2404–2410, 2000.
9. Feng L, Sun W, Xia Y, Tang W, Chanmugan P, Soyoola E, Wilson CB, and Hwang D. Cloning two isoforms of rat cyclooxygenase: differential regulation of their expression. *Arch Biochem Biophys* 307: 361–368, 1993.
10. Franse LV, Pahor M, Di Bari M, Shorr RI, Wan JY, Somes GW, and Applegate WB. Serum uric acid, diuretic treatment and risk of cardiovascular events in the Systolic Hypertension in the Elderly Program. *J Hypertens* 18: 1149–1154, 2000.
11. Goldblatt H. The origin of hypertension. *Physiol Rev* 27: 120–165, 1942.
12. Griffin KA, Picken M, and Bidani AK. Radiotelemetric BP monitoring, antihypertensives, and glomeruloprotection in the remnant kidney model. *Kidney Int* 46: 1010–1018, 1994.
13. Henry RJ, Sobel C, and Kim J. A modified carbonate phosphotungstate method for the determination of uric acid and comparison with the spectrophotometric uricase method. *Am J Clin Pathol* 28: 152–160, 1957.
14. Mazzali M, Hughes J, Kim YG, Jefferson JA, Kang DK, Gordon KL, Lan HY, Kivlighn S, and Johnson RJ. Elevated uric acid increases blood pressure in the rat by a novel crystal-independent mechanism. *Hypertension* 38: 1101–1106, 2001.
15. Mazzali M, Kim YG, Suga S, Gordon KL, Kang DK, Jefferson JA, Hughes J, Kivlighn SD, Lan HY, and Johnson RJ. Hyperuricemia exacerbates chronic cyclosporine nephropathy. *Transplantation* 71: 901–905, 2001.
16. Messerli FH, Frohlich ED, Dreslinski GR, Suarez DH, and Aristimuno GG. Serum uric acid in essential hypertension: an indicator of renal vascular involvement. *Ann Intern Med* 93: 817–821, 1980.
17. Mulvany MJ. Vascular remodeling of resistance vessels: can we define this? *J Cardiovasc Res* 41: 9–13, 1999.
18. Owens GK. Determinants of angiotensin II induced hypertrophy versus hyperplasia in vascular smooth muscle. *Drug Dev Res* 29: 83–87, 1993.
19. Perera GA. Hypertensive vascular disease: description and natural history. *J Chron Dis* 1: 33–42, 1955.
20. Puig JG, Mateos F, Buno A, Ortega R, Rodriguez F, and DalRe R. Effect of eprosartan and losartan on uric acid metabolism in patients with essential hypertension. *J Hypertens* 17: 1033–1039, 1999.
21. Rao GN, Corson MA, and Berk BC. Uric acid stimulates vascular smooth muscle cell proliferation by increasing platelet derived growth factor A-chain expression. *J Biol Chem* 266: 8604–8608, 1991.
22. Rich M. Uric acid: is it a risk factor for cardiovascular disease? *Am J Cardiol* 85: 1018–1021, 2000.
23. Saito I, Saruta T, Kondo K, Nakamura R, Oguro T, Yamagami K, Ozawa Y, and Kato E. Serum uric acid and the renin-angiotensin system in hypertension. *J Am Geriatr Soc* 26: 241–247, 1976.
24. Schiffrin EL and Hayoz D. How to assess vascular remodeling in small and medium sized arteries in humans. *J Hypertens* 15: 571–584, 1997.
25. Skov K, Fenger-Gron J, and Mulvany MJ. Effects of angiotensin converting enzyme inhibitor, a calcium antagonist and an endothelin receptor antagonist on renal afferent arteriolar structure. *Hypertension* 28: 464–471, 1996.
26. Sommers SM, Relman R, and Smithwick RH. Histologic studies of kidney biopsy specimens from patients with hypertension. *Am J Pathol* 34: 685–715, 1958.
27. Weir MR, Flack JM, and Applegate WB. Tolerability, safety and quality of life and hypertensive therapy: the case for low-dose diuretics. *Am J Med* 101: 83S–92S, 1996.
28. Welch WJ, Wilcox CS, and Thomson SC. Nitric oxide and tubuloglomerular feedback. *Semin Nephrol* 19: 251–262, 1999.
29. Wu X, Muzny DM, Lee CC, and Caskey CT. Two independent mutational events in the loss of urate oxidase during hominoid evolution. *J Mol Evol* 34: 78–84, 1992.